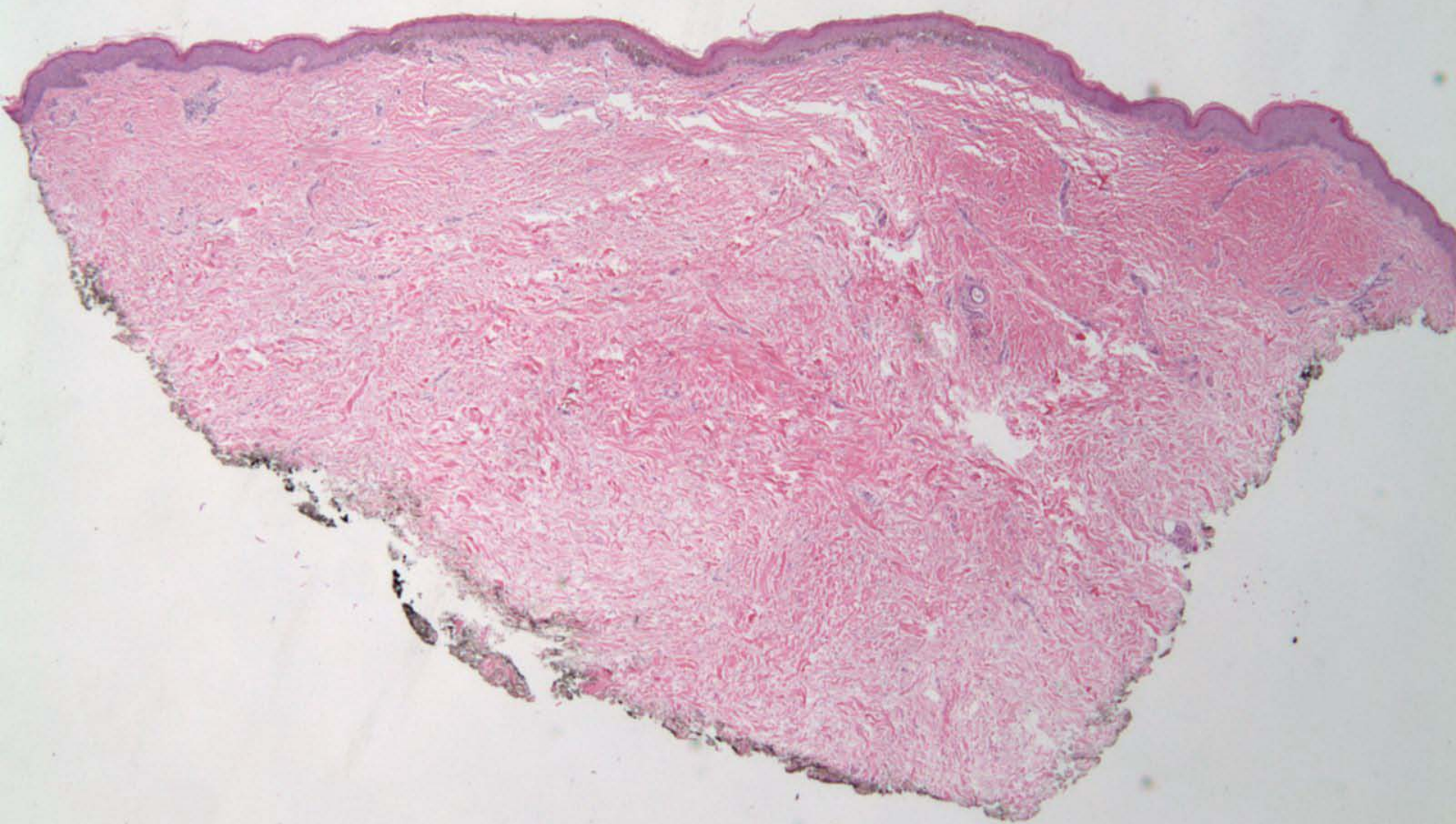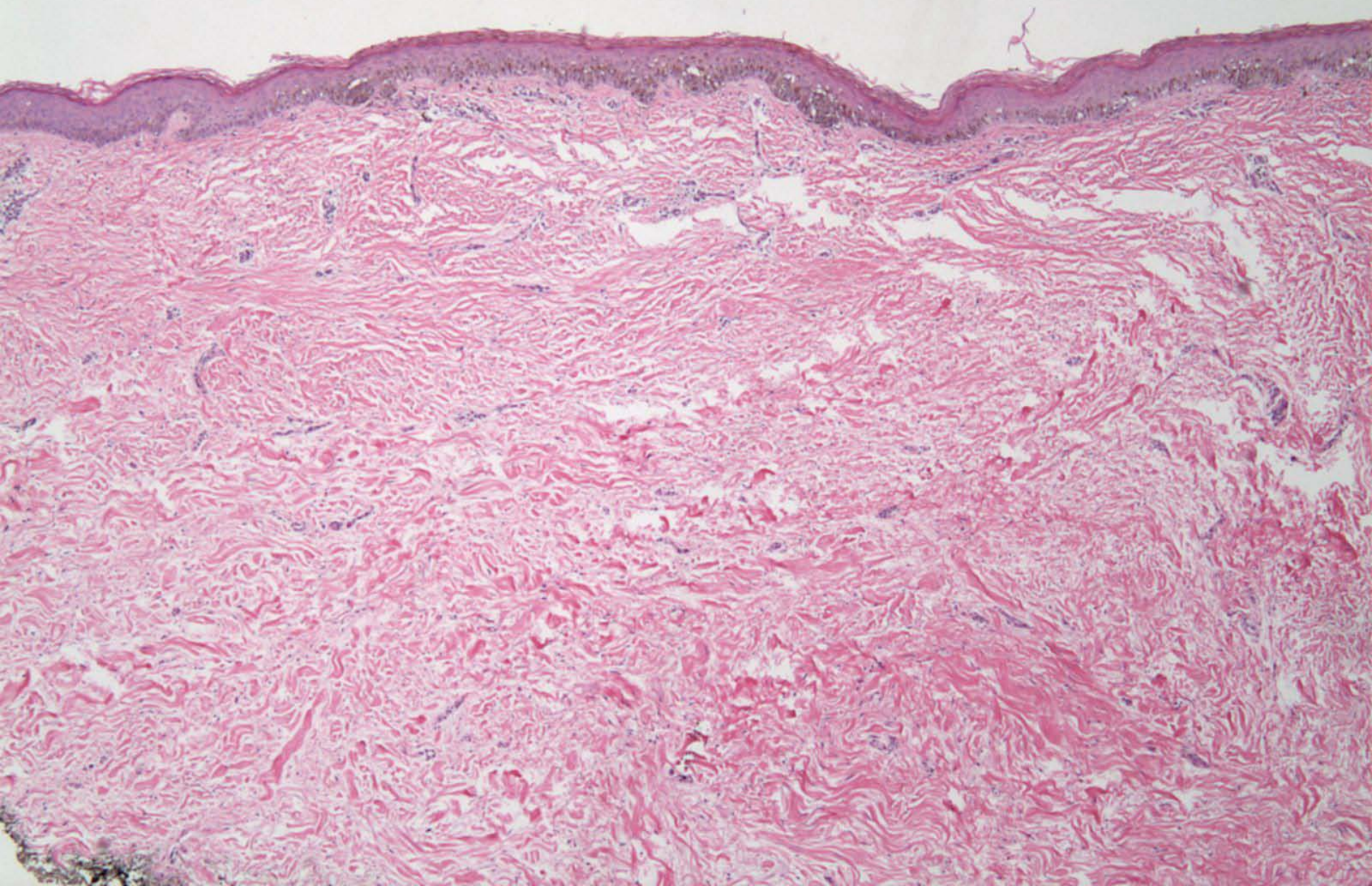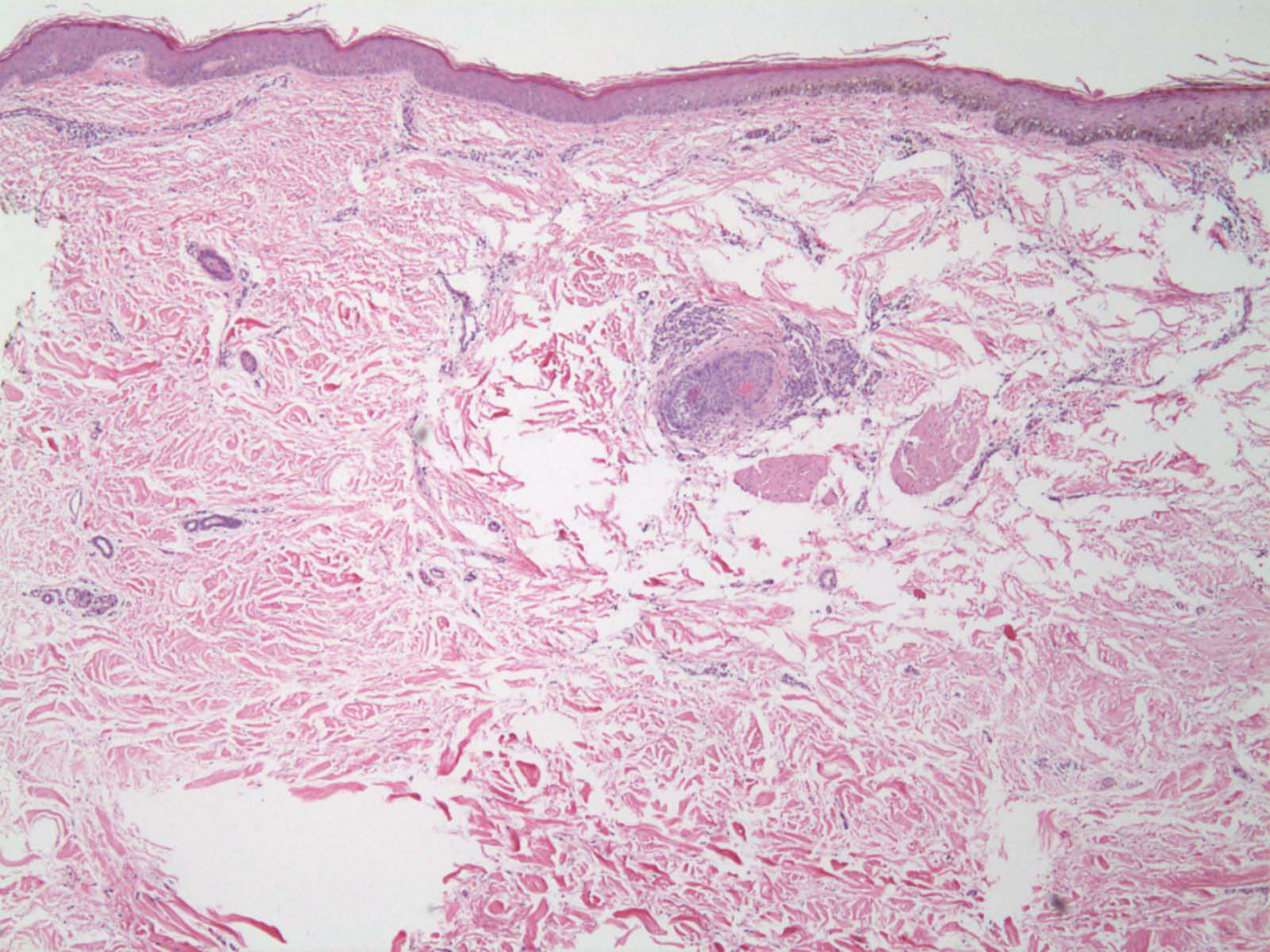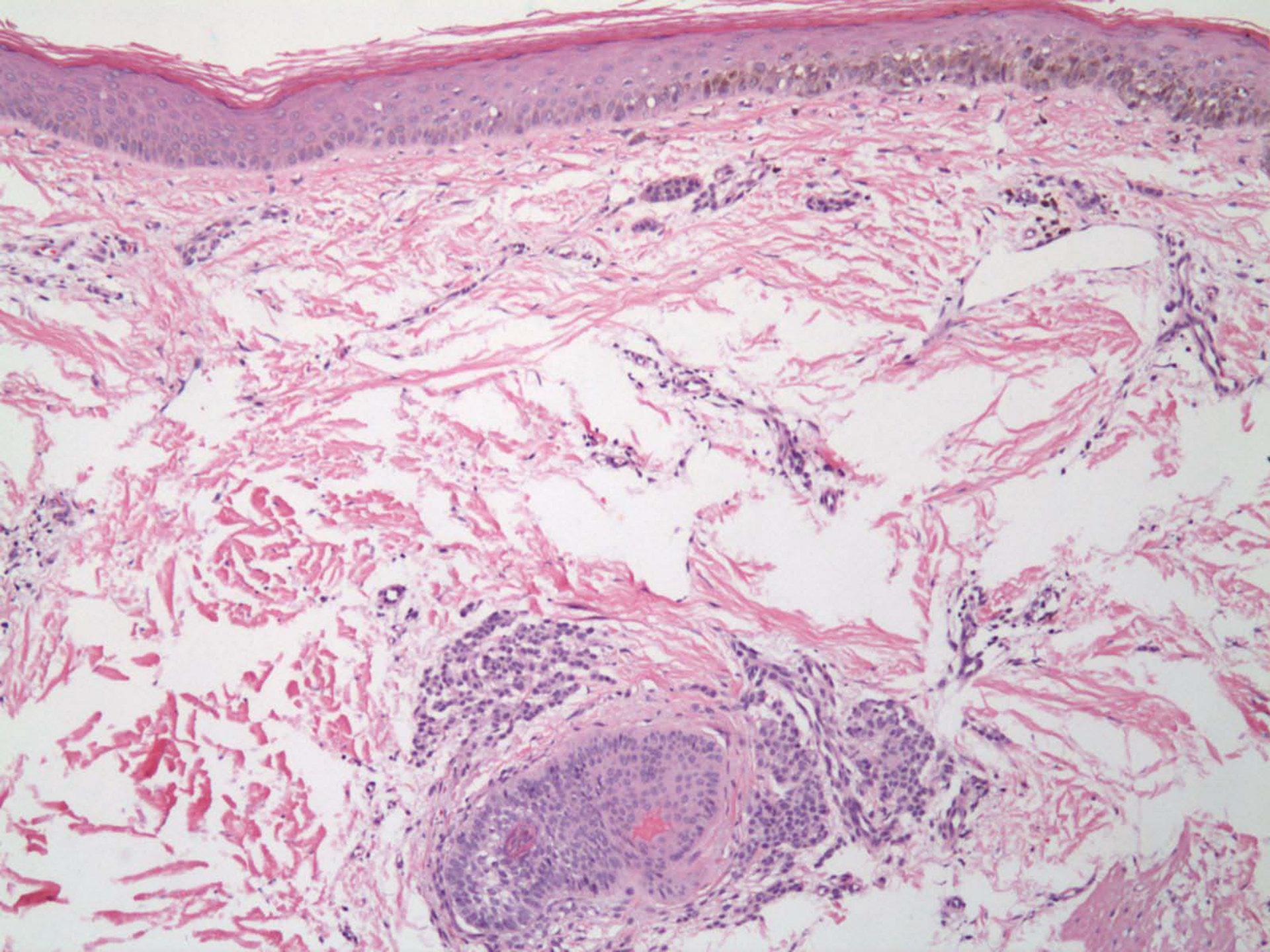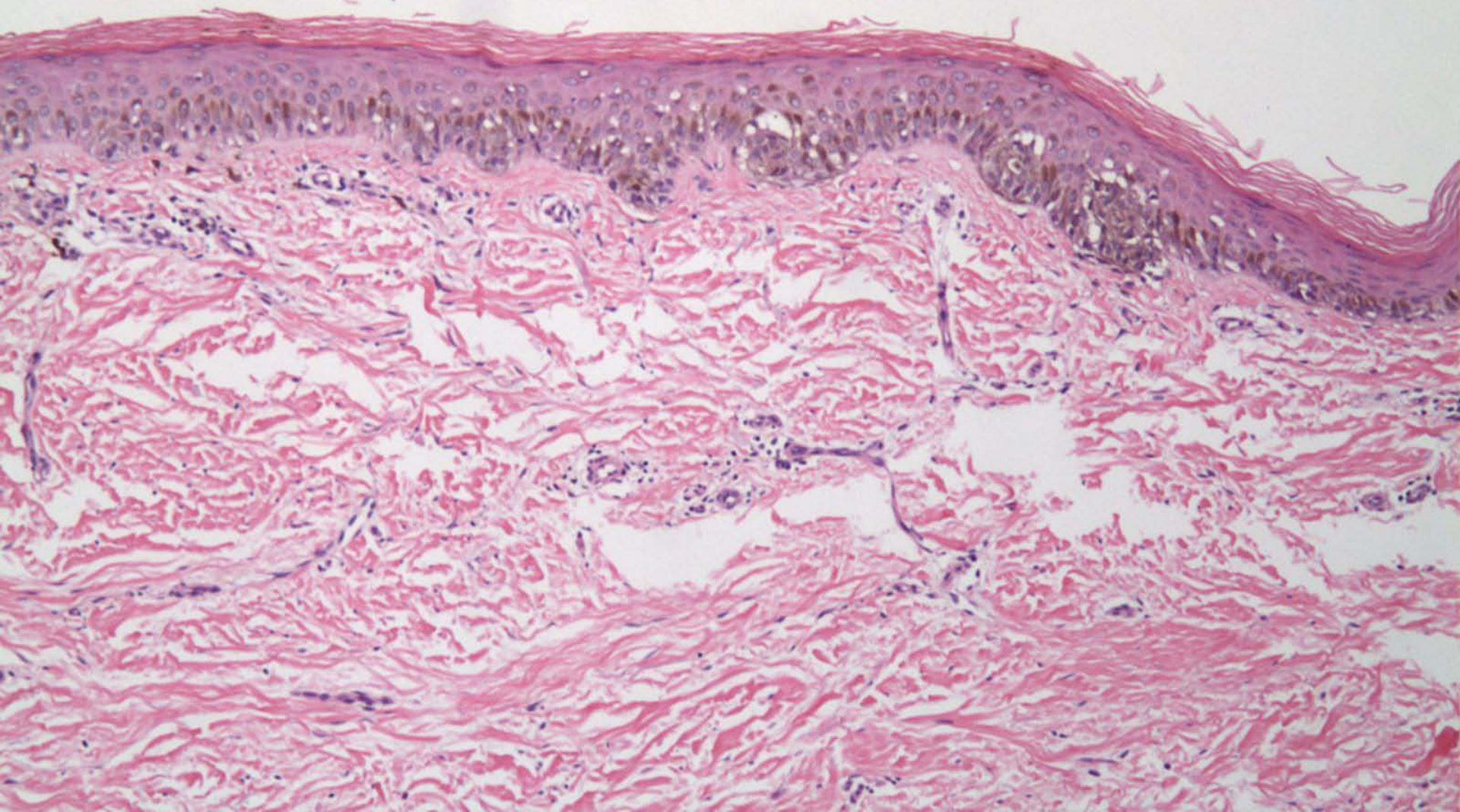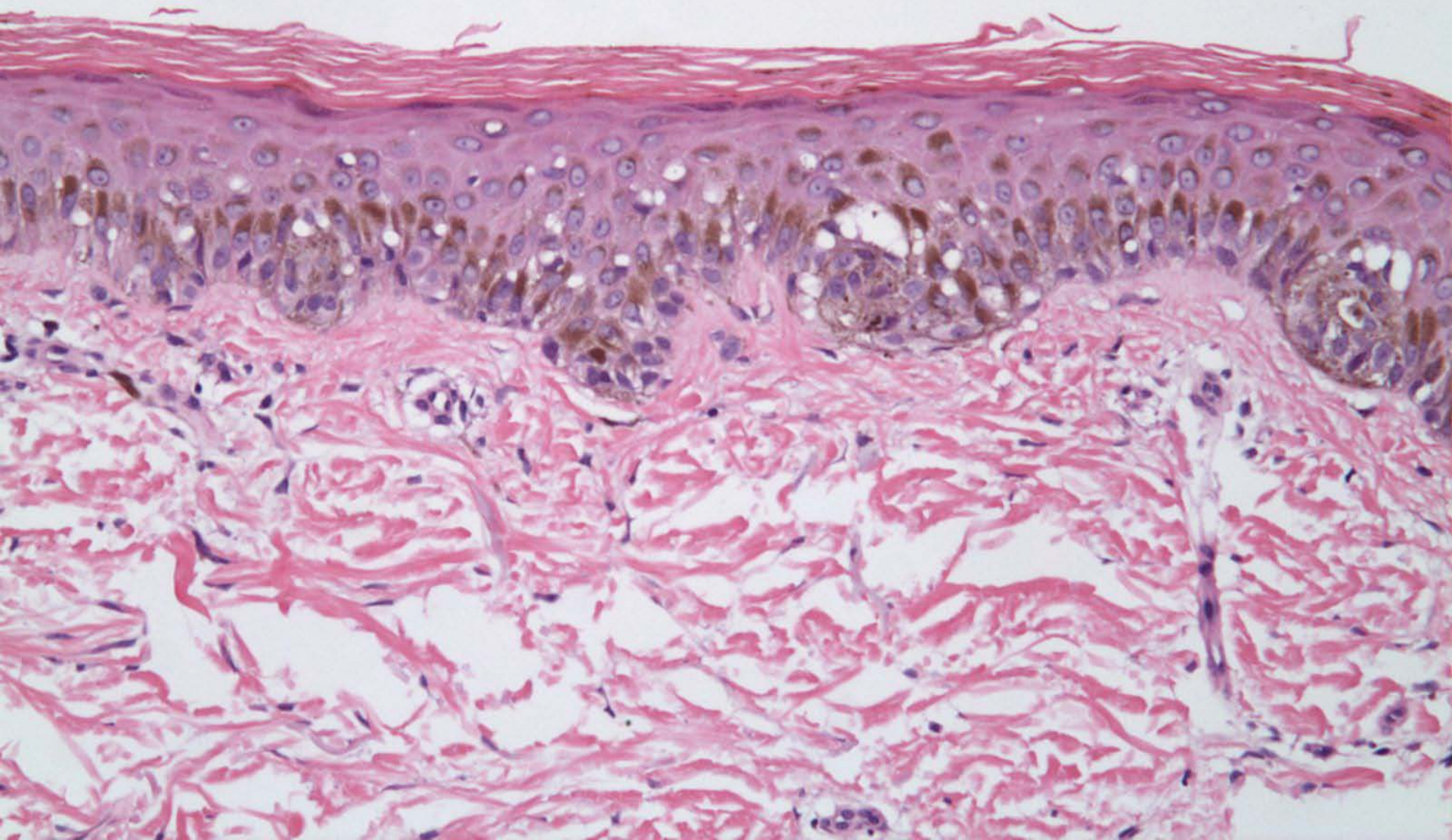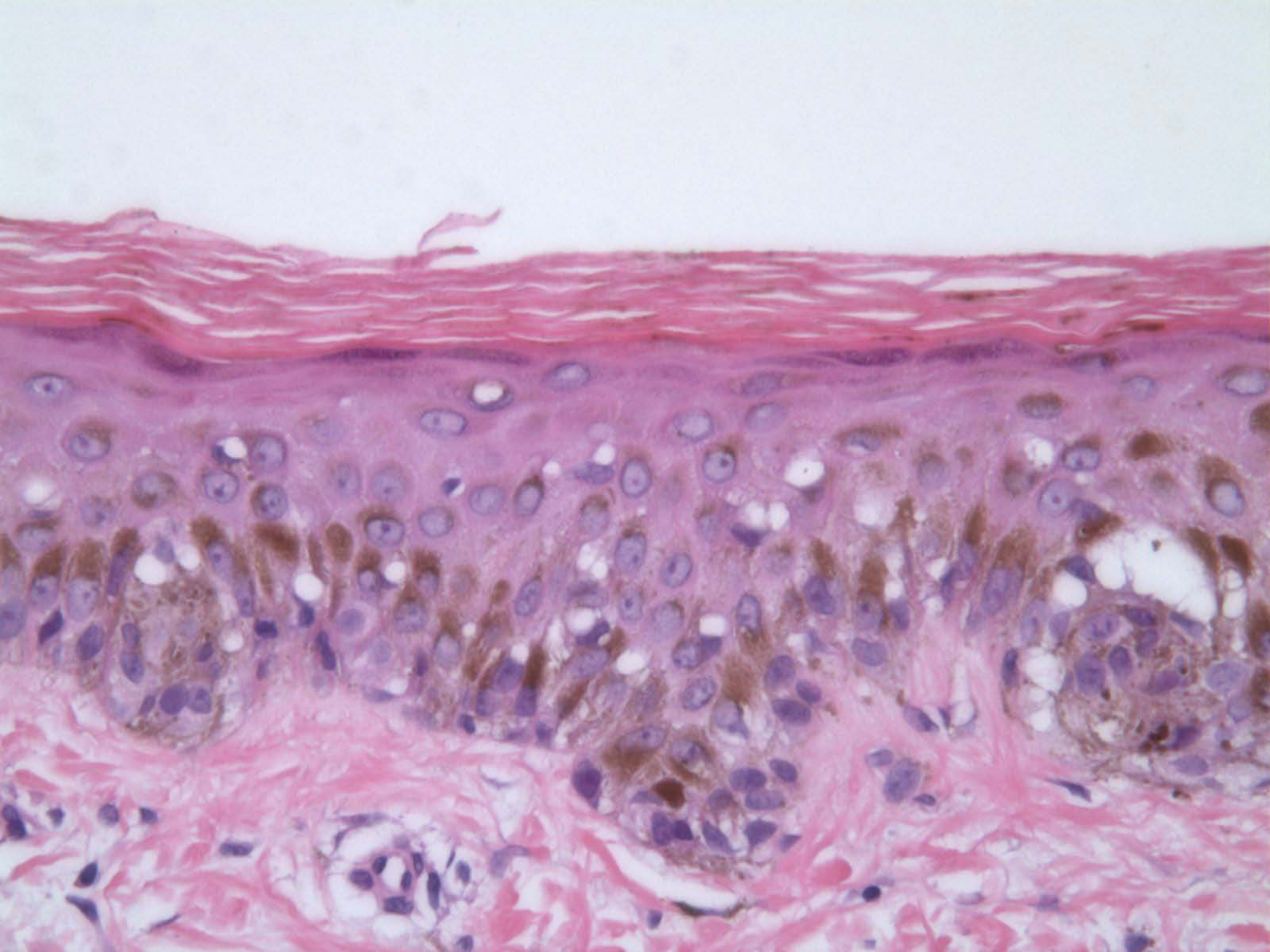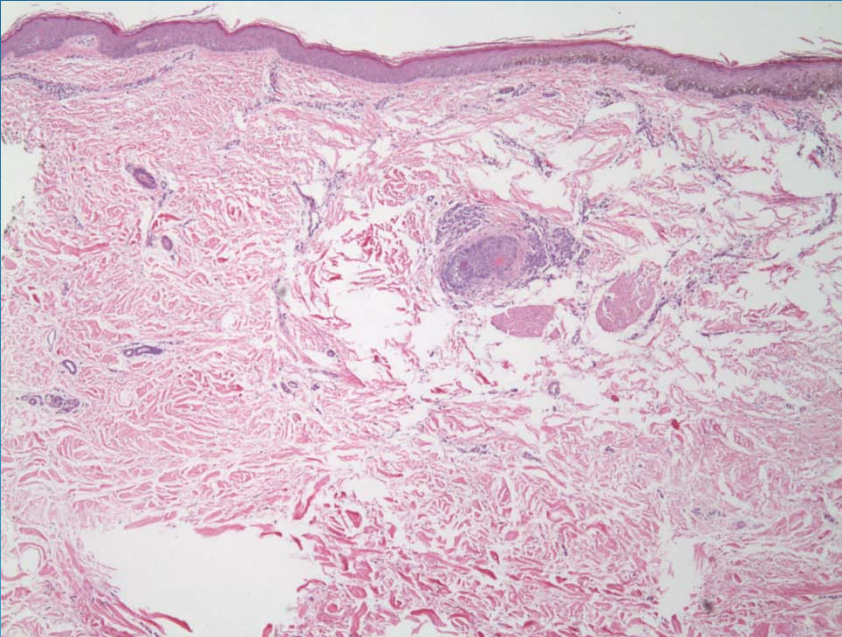


Recurrent Nevus

Pearls



- Flattened epidermis with scar underneath
- Small focus of very pigmented melanocytic proliferation with or without dermal nevus under scar